
K ALUBAIDI*
G CLARKE
A JAMIL
E GHAREEB**

CLINICAL TRIAL
DECEMBER 2008

A NEW HAEMORRHOID BANDING DEVICE

 **Haemoband**
SURGICAL

Background

Band Ligation (BL) for haemorrhoids has proved to be the most successful treatment for 1st, 2nd and 3rd degrees of haemorrhoids. 4th degree haemorrhoids are treated by surgical methods. In this study we are using a new product, Haemoband (Haemoband Surgical Ltd) to test its efficacy and easiness of use.

Methods

Patients were randomly chosen for this study from rectal bleeding clinics and endoscopy lists. On diagnosis of haemorrhoids by proctoscopy, these patients were offered the treatment and treated by multiple BL.

* Mr Alubaidi, Staff Grade in Surgery

** Declaration of interest: E Ghareeb developed the Haemoband

Results

50 patients were treated by BL for 2nd and mostly 3rd degree haemorrhoids. All patients needed 2-3 haemorrhoids banded. 45 patients (90%) were successfully treated. 38(76%) patients stated that they had no pain or discomfort and 5(10%) had very slight discomfort. 47 (95%) did not need coming back for another treatment, if needed. 48 (96%) of the procedures took less than 2 minutes to complete.

Conclusion

The Haemoband is an easy to use instrument for banding haemorrhoids. The procedure was well tolerated by patients for its efficiency and speed. The instrument was used successfully and easily by doctors in their first years in training and we feel it can be successfully used by General Practitioners and trained specialist nurses. The success rate for the Haemoband was significantly higher than previously published for BL.

Introduction

Barron, Dublin Ireland, introduced BL in the early sixties². It has proved over the years to be the most successful, non-operative, method of treating 1st, 2nd and 3rd degree haemorrhoids².

4th degree haemorrhoids are treated surgically¹.

The success rate for BL reaches 78% of cases; the rest would need a 2nd treatment².

It has always been a relatively difficult procedure because of the equipment used. The latter needed two people, one to hold the proctoscope and the operator to apply the bands using two instruments: one to draw the tissue and the other to fire the band. The instrument needed reloading of the bands after each application to each haemorrhoid¹.

New equipment development provided instruments, which use suction to draw the tissue, so the operator uses one hand to hold the proctoscope and the other to apply the suction and fire the band. The difficulty in stretching the rubber band to load the firing mechanism of the instrument continued to be a major one. The time lapsed in repeating this process, while the patient has the scope inserted or repeatedly reinserted, forced some operators to recommend applying one band during each visit³.

The introduction of new equipment, which can fire multiple bands automatically without the need to reload, made the procedure easier, quicker and less uncomfortable to the patient and staff and allowed more precise application of the bands.

We demonstrate here an instrument (The Haemoband), which has 4 preloaded bands. The instrument automatically reloads after each firing, cancelling the need to withdraw completely the proctoscope after each firing. It also automatically activates the suction before each firing, further simplifying the procedure. We studied the results of treatment, patient's degree of discomfort and the speed of the procedure.

Patients and methods

50 patients were chosen randomly through our rectal bleeding clinics or endoscopy lists.

All patients had rigid or flexible sigmoidoscopy or colonoscopy, according to our protocol for rectal bleeding clinics, which was designed using different accepted guidelines, and proctoscopy.

1st, 2nd and 3rd degree haemorrhoids were banded using the Haemoband, Haemoband Surgical Ltd, which holds 4 latex-free rubber bands on its firing mechanism.

During the procedure the bands were applied onto the neck of each haemorrhoid and enough tissue (2-4mm) was included to hold the band in place. The necrosis and tissue reaction from the band produces a fibrous tissue reaction, which retracts the redundant, prolapsed mucosa and glues it to the rectal wall. It also reduces the size of the venous plexus in the haemorrhoid tissue.

A protocol was devised to record the presenting symptoms, procedure time, number of haemorrhoids and their degree, the number of rubber bands applied and the level of patients discomfort or pain during and just after the procedure.

Patients were followed up either in the surgical outpatient clinic or contacted by phone to complete the protocol form.

They were asked if they were completely improved that their symptoms have completely gone, slightly improved or if there were no improvement. They were also asked that if they were to need any further similar treatment in the future, would they agree or not.

The total number of patients is 50, 24 males and 26 females. Age ranged from 18 to 79 years. The duration of the disease ranged from 4 months to 15 years.

2 ladies developed their haemorrhoids after pregnancy and 20 patients complained of chronic constipation.

4 patients had 2 haemorrhoids and 46 had 3 haemorrhoids.

Patients presentation

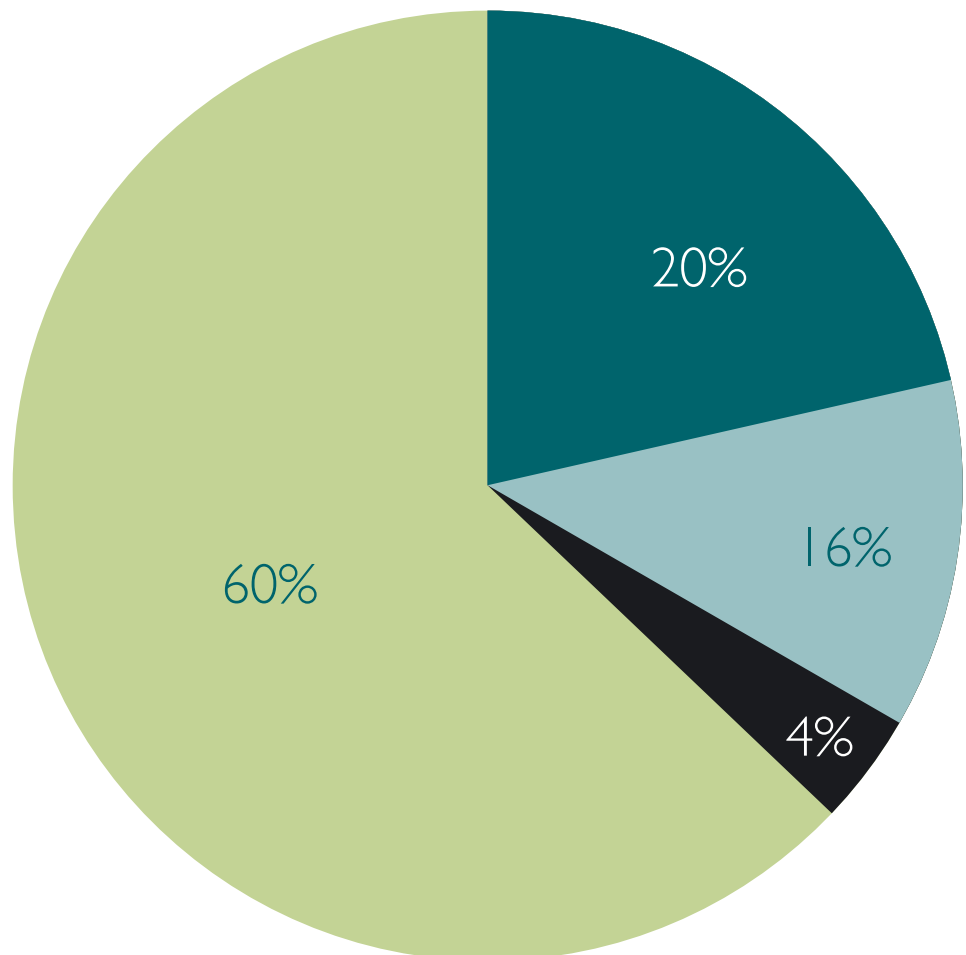
2 patients complained of associated anal pain and 48 complained of fresh PR bleeding.

8 patients complained of mucus secretions PR and 10 patients complained of perineal irritation.

4 patients had 2 rubber bands applied and 46 had 3 applied during the same session.

48 procedures took less than 2 minutes; one took 2-4 minutes and one 4-6 minutes.

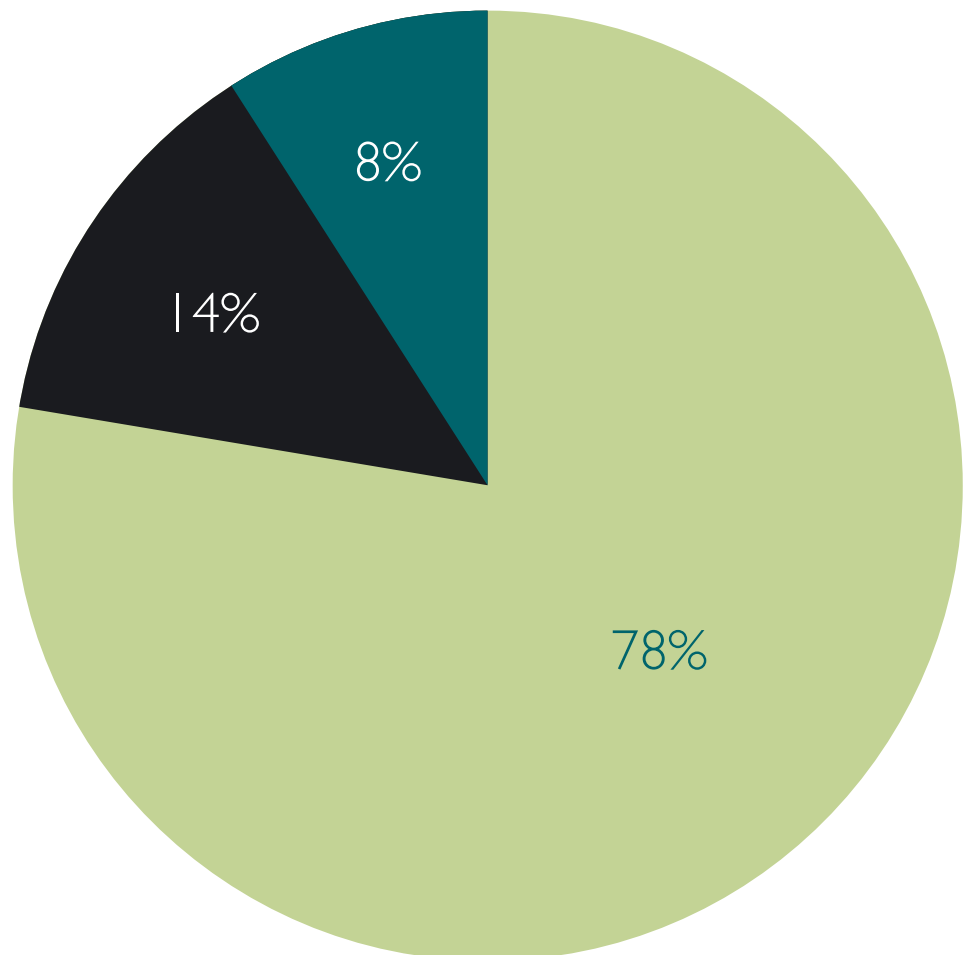
-
- PR Bleeding and Irritation
 - PR Bleeding and Mucus Secretion
 - PR Bleeding and Anal Pain
 - PR Bleeding only



Results

7 patients complained of slight pain during the procedure and 4 patients complained of very slight pain. 39 did not complain, on asking, of any pain or discomfort.

-
- No Pain
 - Slight Pain
 - Very Slight Discomfort



Treatment success

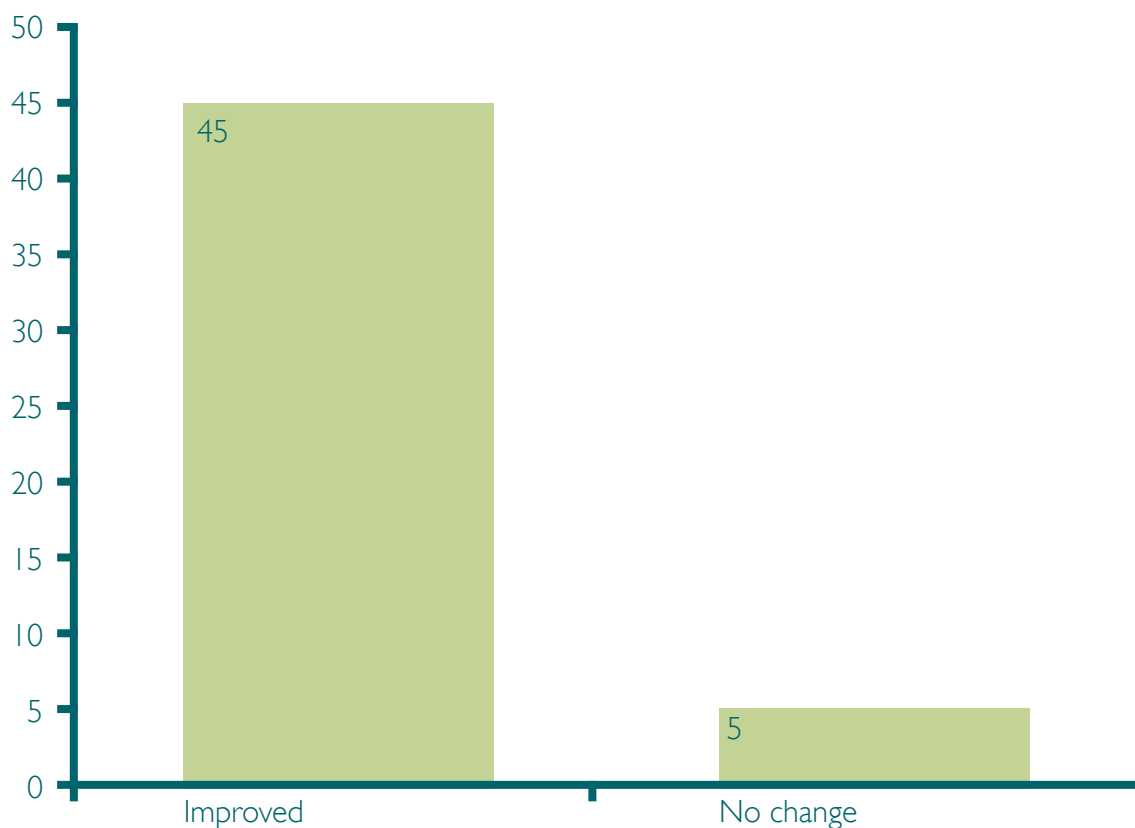
5 patients said that there was no change in their symptoms (PR bleeding and Mucus) 6 weeks after the treatment (10%) and 45 said that they had completely improved with a cure rate of 90 %, without any symptoms.

None of the patients complained of continued pain or discomfort after the procedure, even the ones who had slight or very slight pain during the procedure.

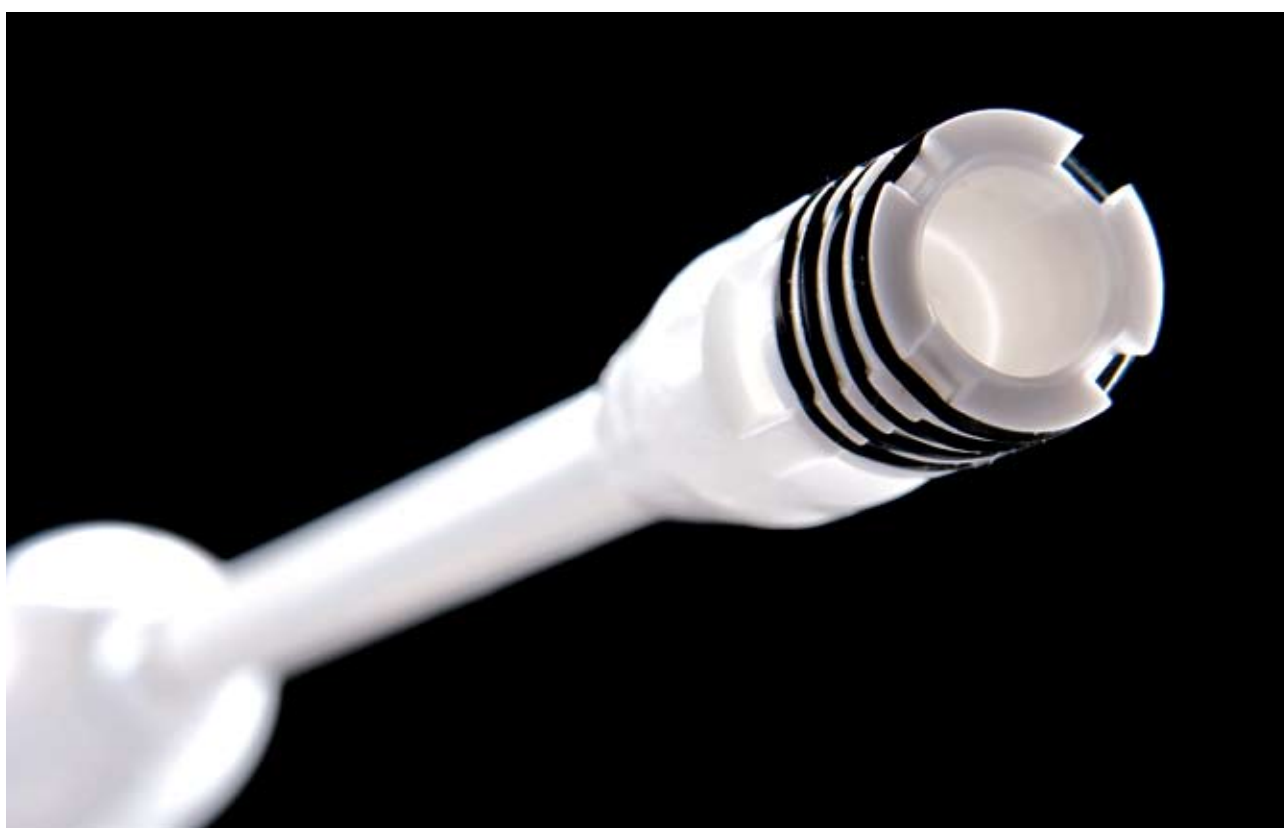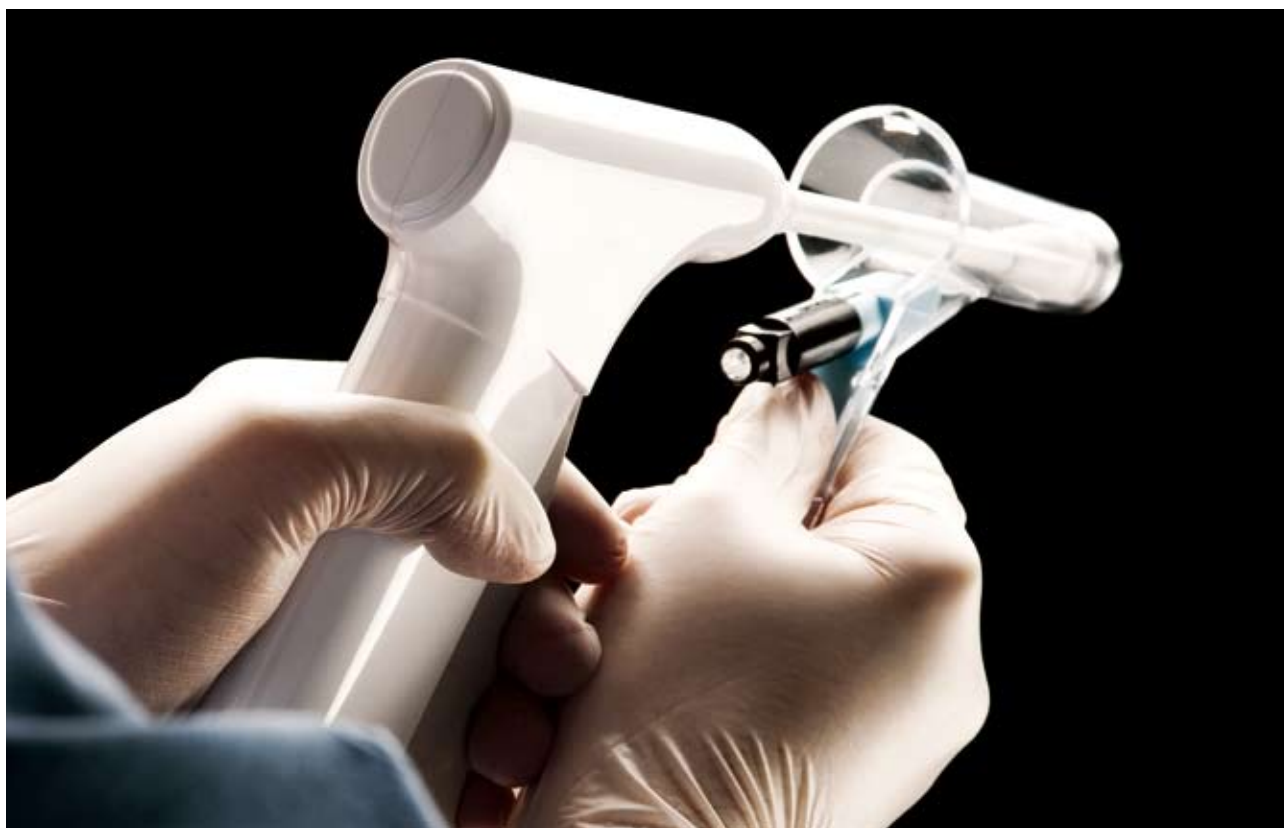All patients with perianal irritation improved.

When asked if they would have the procedure repeated, 47 answered YES and 3 NO.

There were no complications recorded from these patients.



The Haemoband



Discussion

Haemorrhoids are one of the most common surgical diseases¹. It is estimated that it would affect 50-60% of the population of the United States at one stage of their lives^{4,5,6,7}. They equally affect different races and both genders. Chronic constipation, pregnancy¹ and even the erect human posture thought to be contributing factors in their aetiology.^{2,8}

Haemorrhoids are merely prolapsed mucosa, which covers congested venous plexus². The latter is normally present in the anus above the dentate line and supposed to be playing an important role in anal continence.

BL has been in practice for over 40 years and proved to be one of the most effective methods for treating 1st, 2nd and 3rd degree haemorrhoids². The problem with this method of treatment has always been the awkwardness of its application. That resulted in the introduction of other methods as Injection Sclerotherapy, Cryosurgery, Laser treatment, Infrared coagulation and Radiofrequency coagulation.^{9,10,11}

Some claimed to have the same success rate as BL, but needed several outpatient sessions to apply the treatment^{3,9,10,11}

With the introduction of new devices for BL, this method has continued to be the most popular and cost effective method of treatment.

We used an instrument, which does not need reloading or manual activation of suction and easy to use, so the time and patient discomfort as a result, has been largely reduced.

Our results are better than the previously published for this method², we believe because of the better control during the procedure of firing the bands, while the patient is completely relaxed with minimal or no discomfort.

We did not have recorded complications for the same reasons and because of the small number of patients, as complications like bleeding or perineal sepsis occur in a very small number of patients.^{12,13}

References

1. Barron J2 office ligation of internal Haemorrhoids ,Am j surg. 1963 105: 563-673

2. P finninger; Modern treatment for Internal Haemorrhoids, BMJ, 1997, 314: 1211 (26 april)

3. Dennison A, Whiston RJ, Rooney S, Chadderton RD, Wherry DC, Morris DL. A randomised comparison of infrared photocoagulation with bipolar diathermy for outpatient treatment of haemorrhoids. Dis Colon Rectum 1990;33:32-4

4. Yang R, Migikovsky B, Peicher J, Laine L. Randomised, prospective trial of direct current versus bipolar electrocoagulation for bleeding internal haemorrhoids. Gastrointest Endosc 1993;39:766-9

5. Corman ML. Colon and Rectal surgery> 4th Ed. Philadelphia: Lippincott- Raven, 1998:147-205

6. Salvati EP. Non-operative management of haemorrhoids. Dis Colon rectum 1999;42:989-993 Beck DE. Haemorrhoidal disease In : Beck DE, Wexner SD, eds. Fundamentals of anorectal surgery. 2nd ed. London: WB Saunders, 1998:237-253 lain GM Cleator; Maria M Cleator: The Cleator clinic. On the web: Banding haemorrhoids using the O'Regan disposable bander

7. Bleday R, Pena JP, Rothenberger DA, Goldberg SM, buls JG. Symptomatic Haemorrhoids, Current Incidence and complications of operative therapy. Dis Colon rectum 1992: 35:477-81

8. Smith LE. Haemorrhoidectomy with Lasers and other contemporary modalities. Surg Clin North Am 1992;3:665-79 Schussman LC, Lutz LJ. Outpatient management of haemorrhoids. Prim care 1986;13:527-41

9. Liebach JR, Cerda JJ. Haemorrhoids: modern treatment methods. Hosp Med 1991: August: 53-68

10. Norman DA, Newton R, Nicholas GV. Direct current electrotherapy of internal haemorrhoids: an effective, safe and painless outpatient approach Am J Gastroenteral 1989;84:482-Bullock N. Impotence after sclerotherapy of haemorrhoids: case rport. BMJ 1997: 314:419

11. Templeton JL, Spence RJ, Kennedy TL, et al. comparison of infra-red coagulation and rubber band ligation for 1st and 2nd degree haemorrhoids. Am J Gastrenteral 1989;84:475-81

The Mount Business Park
2 Woodstock Link
Belfast BT6 8DD
Northern Ireland

T: +44 (0)28 9073 7283
F: +44 (0)28 9073 7282
sales@haemobandsurgical.com
www.haemobandsurgical.com

